

# Effects of various submucous resection techniques of septal cartilage on nasal tip projection

Richard A. Zoumalan, MD<sup>1</sup>, Luc G.T. Morris, MD<sup>2</sup>, Daniel M. Zeitler, MD<sup>3</sup>, Anil R. Shah, MD<sup>4</sup>

**Background:** There is little research which determines whether septoplasty affects nasal projection.

**Objectives:** To assess the effect of various septoplasty (submucous resection, SMR) techniques on nasal tip projection in a fresh cadaver model.

**Methods:** The nasal tip projection was measured on 6 fresh cadaver heads and compared postoperatively after a sequence of submucous septoplasty maneuvers. Five different septoplasty techniques were performed in the same sequence on each cadaver. After each technique, measurements were performed.

**Results:** Removal of a central square piece of quadrangular cartilage resulted in a loss of projection in 3 in 6 (50%) heads, with average loss of 7.76%. Removal of additional cartilage along the bony cartilaginous junction resulted in no loss of projection. Removing more septum along the floor resulted caused a change loss in nasal projection in 1 in 6 (17%) cadavers. Removing the remaining septum, except for the L-strut resulted in a loss of projection in 2 in 6 (33%)

heads with an average percent change in tip projection of 9.08%. Swinging door technique resulted in a loss of projection in 1 cadaver (17%), with loss of 6.25%. All 6 cadavers experienced loss of nasal projection. When all maneuvers were taken in total, there was a statically significant average decrease in projection of 8.93% (range, 5.00-13.04%,  $p = 0.008$ ).

**Conclusion:** Primary septoplasty carries a risk of nasal tip projection, with certain maneuvers carrying higher risk. © 2011 ARS-AAOA, LLC.

**Key Words:** septal cartilage; nasal tip projection; submucous resection techniques; techniques; rhinoplasty; septum

#### How to Cite this Article:

Zoumalan RA, Morris LGT, Zeitler DM, Shah AR. Effects of various submucous resection techniques of septal cartilage on nasal tip projection. *Int Forum Allergy Rhinol*, 2011; 1:78-82

Approximately 80% of the general population has septal deviation, with up to one-third suffering from some

degree of anatomic nasal obstruction. Many patients seeking nasal septal surgery desire operative intervention not because of a desire to alter the aesthetic character of their nose, but simply to correct anatomic narrowing of the nasal airway which may be contributing to the inability to breathe from the nose.

Septoplasty is a broad term that refers to a variety of operations used to straighten or remove deviated portions of cartilage for the nasal airway to become more widely patent. Perhaps the most common variant of the septoplasty is a submucous resection (SMR), whereby a central portion of cartilage is removed, preserving at least 2 cm of caudal and dorsal septal cartilage (ie, L-strut). A central tenant in many otolaryngology textbooks is that maintenance of a strong L-strut will prevent any postoperative changes in the appearance of the nose or affect nasal tip projection.

The possibility of septoplasty having an aesthetic outcome on a patient's nose is often downplayed, with many surgeons who perform septoplasty not taking preoperative and postoperative photography. During consent for septal surgery, only 20% to 23% of ear, nose, and throat

<sup>1</sup>Department of Otolaryngology-Head and Neck Surgery, Division of Facial Plastic and Reconstructive Surgery. University of Washington, Seattle, WA; <sup>2</sup>Department of Otolaryngology-Head and Neck Surgery, Division of Neuro-Otology. University of Miami. Miami, FL;

<sup>3</sup>Department of Otolaryngology-Head and Neck Surgery, Memorial Sloan Kettering Cancer Center. New York, NY; <sup>4</sup>Division of Facial Plastic Surgery, Department of Otolaryngology-Head and Neck Surgery, University of Chicago, Chicago, IL.

Correspondence to: Richard Zoumalan, Department of Otolaryngology, Head and Neck Surgery, Division of Facial Plastic and Reconstructive Surgery, University of Washington, Seattle, WA; e-mail: rzoumalan@gmail.com

This study was performed while all the above authors were at New York University in the Department of Otolaryngology-Head and Neck Surgery.

Presented at the annual American Rhinologic Society Meeting as an oral presentation in Las Vegas, NV in April, 2010. Potential conflict of interest: None provided.

Received: 10 May 2010; Revised: 18 July 2010; Accepted: 19 August 2010  
DOI: 10.1002/alar.20009

View this article online at [wileyonlinelibrary.com](http://wileyonlinelibrary.com).

(ENT) surgeons discuss the potential complication of aesthetic change.<sup>1,2</sup> Previous prospective analysis reports that the rate of cosmetic effect from septal surgery is in the range of 0% to 21%.<sup>3,4</sup> A survey by Peacock<sup>5</sup> of 409 patients revealed that 21.8% of patients who underwent septoplasty had noticed some change in shape of the nose. Phillips<sup>3</sup> also found a 21% rate of cosmetic change of the nose in 41 patients who were surveyed after surgery. Three said the change was noticed immediately, and 6 noticed it some months later. However, only 1 patient had obvious change when preoperative and postoperative pictures were compared. There was no mention of objective measurements in the patients.<sup>3</sup> In a questionnaire study by Thomas,<sup>6</sup> which evaluated 78 patients over a 2-year period, 17% reported a change in the external appearance of their nose which was attributed to SMR.

Although there is abundant literature on nasal tip projection and the factors that affect it, the role of the cartilaginous nasal septum in providing nasal tip projection is not well delineated. In fact, the standard lists outlining both the major and minor tip supporting mechanisms do not list the nasal septum or septal strength as a factor. Several authors who have looked at nasal tip projection have found that septoplasty was the most disruptive factor in terms of loss of tip projection.<sup>7</sup> However, in this study, it is not clear from the authors what approach to the septum took place.

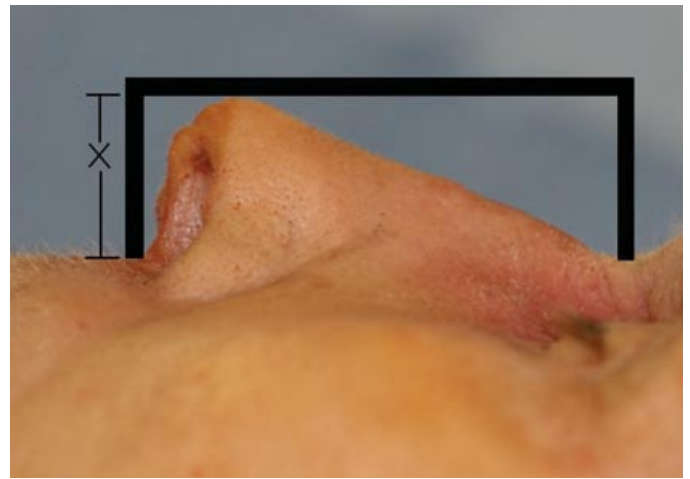
One study did attempt an objective measurement of the aesthetic sequelae of septoplasty. Daudia et al.<sup>8</sup> found a 39.5% rate of minor change ( $\leq 2$  mm) and a 4.5% rate of major change ( $\geq 3$  mm) in tip projection in patients who underwent various types of nasal septal surgery. In this study, various techniques were used by different surgeons, and revision nasal surgeries were included. While this study points to the fact that the septum may play a role in nasal tip projection, it does not determine which maneuvers in septoplasty lead to a loss of nasal tip projection.

The primary aim of this study was to objectively measure changes in nasal tip projection as a result of 5 different septoplasty techniques to determine the impact each maneuver has on nasal tip projection. This is the first study which analyzes a variety of maneuvers used in septoplasty on nasal projection in a standardized fashion.

## Materials and methods

A total of 6 fresh cadaver heads were used for this study. All septoplasty operations were performed by the same senior surgeon for consistency (A.R.S.) while all measurements performed by the same surgeons for consistency (D.M.Z., L.G.T.M., R.A.Z.).

Nasal tip projection was calculated as the distance from the bony premaxilla to the nasal tip. In order to yield standardized measurements, we determined that the nasal tip corresponded to the domal highlights. First, a straight ruler was placed in a plane perpendicular to the face from the fixed bony points of the subnasale at the premaxilla and at the glabella. A line was created perpendicular to



**FIGURE 1.** This is how measurements of projection were taken. Two rulers were placed on the patient perpendicular to the face, 1 on the glabella and 1 on the subnasale. Then another ruler was placed perpendicular to these lines. The distance from premaxilla at subnasale to the line was measured. This value is seen as "X" in the image.

these 2 points and the nasal tip distance was calculated as the distance from the subnasale to the perpendicular line. Figure 1 depicts how projection was recorded. X in the image is the distance from premaxilla to the line drawn perpendicular to both lines. Since there is variation in the soft tissues of each cadaver, the ruler was positioned directly on the premaxilla firmly and tested on each cadaver for accuracy prior to completing the study.

Once the preoperative nasal tip projection was calculated and recorded, we performed all 5 of the septoplasty techniques on all 6 cadaver heads in the following manner. The sequence was chosen because each progressive maneuver was more invasive and to determine the impact on the nose. To begin, a modified hemi-transfixion incision was made with a 15-blade in the left nasal cavity.

A total of 5 different techniques were performed. Technique 1 consisted of the removal of a small central 2-cm  $\times$  2-cm square of cartilage was removed from the septum (abbreviated "square" in Table 1). This technique preserved at least 2 cm of caudal and dorsal septum. In Figure 2, the red square is the portion of the septal cartilage that was removed.

Technique 2 consisted of removal of septal cartilage and bone at the bony cartilaginous junction. Essentially, the quadrangular cartilage was separated at the bony-cartilaginous junction with preservation of at least a 2-cm dorsal cartilaginous strut. Figure 3 shows the blue area which was removed posterior to the square in Technique 1.

Technique 3 consisted of removing a caudal portion of cartilage which preserved a 2-cm segment of caudal support as well as a longer portion along the septal floor. In Figure 4, this area is shown in green.

Technique 4 consisted of removing the portion of septal cartilage along the floor, leaving just a 2-cm caudal and dorsal strut. Figure 5 shows this area in lavender.

**TABLE 1.** Results of each of the maneuvers\*

	Maneuver					
	Square	B-C junction	Caudal	Floor	Swinging door	Total
Cadaver 1,%	13.03 (3 mm)	0.00	0.00	0.00	0.00	13.04 (3 mm)
Cadaver 2,%	0.00	0.00	0.00	13.16 (2.5 mm)	0.00	13.16 (2.5 mm)
Cadaver 3,%	5.26 (1 mm)	0.00	0.00	0.00	0.00	5.26 (1 mm)
Cadaver 4,%	0.00	0.00	0.00	5.00 (1 mm)	0.00	5.00 (1 mm)
Cadaver 5,%	5.00 (1 mm)	0.00	0.00	0.00	0.00	5.00 (1 mm)
Cadaver 6,%	0.00	0.00	5.88 (1 mm)	0.00	6.25 (1 mm)	12.13 (2 mm)
<i>t</i> test	$p = 0.289$		$p = 0.363$	$p = 0.118$	$p = 0.363$	$p = 0.008$
Average	7.76%	0.00	5.88%	9.08%	6.25%	8.93%

\*Values are percentage change of nasal tip projection. The number of the maneuver refers to the technique number mentioned in the manuscript body. Square refers to removal of central square of cartilage. B-C junction refers to removal of septal cartilage at bony-cartilaginous junction. Caudal refers to removing more near the caudal portion of septum. Floor refers to removal of septal cartilage from floor. While each individual maneuver did itself not produce a significantly significant change in nasal tip projection, the total result percent change in nasal tip projection was statistically significant.

Technique 5 consisted of creation of a swinging door, in which the caudal septum is disarticulated from the maxilla and swung to the opposite side. The hemitransfixion incision was not closed. No quilting sutures nor any other maneuver to permanently medialize were performed.

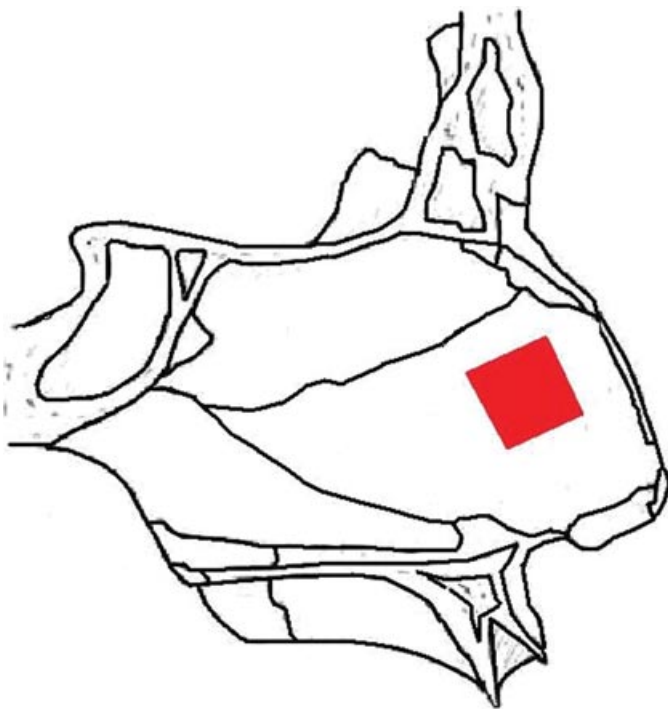
## Results

Six fresh cadaver heads were used in this study (Table 1). When looking at Technique 1, removal of a 1-cm<sup>2</sup> cen-

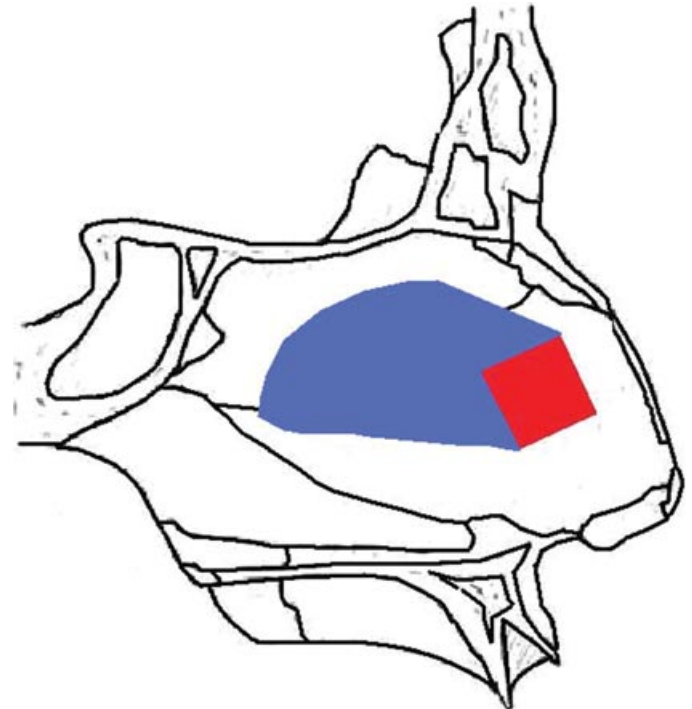
tral piece of quadrangular cartilage, it resulted in a loss of projection in 3 in 6 (50%) of the cadaver heads with an average tip projection loss of 7.76% ( $p = 0.289$ ). The loss of projection was 1 mm in 2 of the heads, and 3 mm in 1 of the heads.

Technique 2, removal of cartilage and bone at the bony-cartilaginous junction did not result in a loss of projection in any of the cadaver heads.

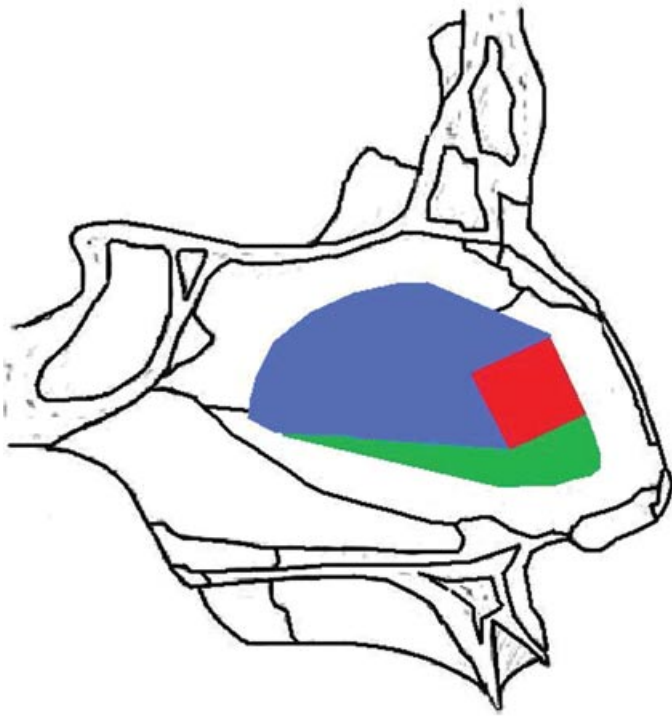
Technique 3, in which more caudal cartilage was removed, resulted in a change in nasal projection in 1 in 6 (17%) of the heads. The 1 cadaver specimen with a change



**FIGURE 2.** This is Technique 1. A central square piece of cartilage was removed.



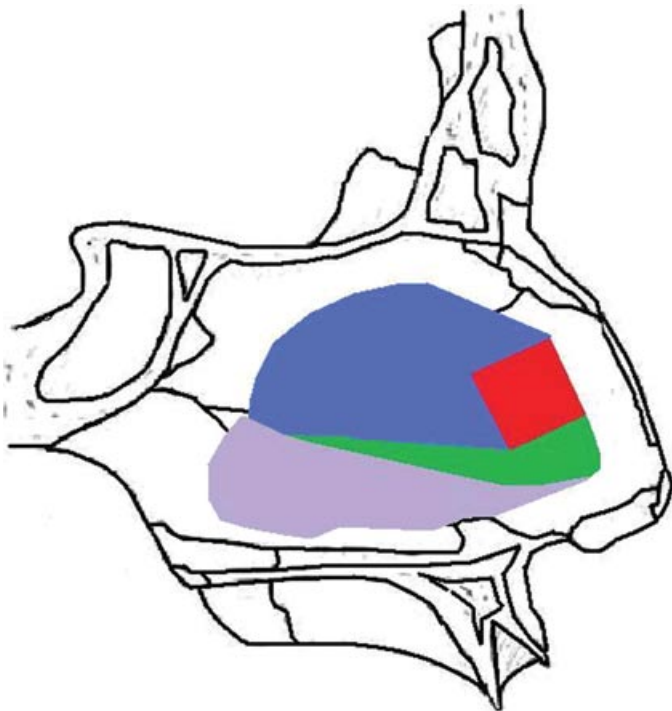
**FIGURE 3.** This is Technique 2. Cartilage and bone at the bony-cartilaginous junction was removed.



**FIGURE 4.** This is Technique 3. More cartilage at the caudal portion of the septum was removed, with care to leave adequate 2 cm of L-strut.

in nasal tip projection demonstrated a 1 mm, or 5.88%, change ( $p = 0.363$ ).

Conversely, in Technique 4, when a down-cut was made and the remainder of septum along the floor was removed, 2



**FIGURE 5.** This is Technique 4. Cartilage and bone at the floor of the nose was removed.

in 6 (33%) of the heads demonstrated loss of tip projection with an average percent change in tip projection of 9.08% ( $p = 0.118$ ). One cadaver head lost 1 mm of projection, while another lost 2.5 mm.

Technique 5, swinging door, resulted in a loss of projection in 1 cadaver (17%), with loss of 1 mm, which was a 6.25% change in projection ( $p = 0.363$ ).

After all aforementioned maneuvers were performed on each cadaver, all 6 cadavers experienced loss of nasal projection. When all maneuvers were taken in total, there was an average decrease in projection of 8.93%, which reached statistical significance ( $p = 0.008$ ). The total loss of projection after all maneuvers ranged from 5% to 13%. It is important to note that all the cadavers lost projection on some level. The maneuvers on which the cadavers lost projection varied from head to head.

## Discussion

SMR of the septal cartilage is 1 of the most common procedures performed by otolaryngologists for relief of nasal obstruction. Additionally, septoplasties are frequently performed in conjunction with a standard rhinoplasty. Thus, both the correct techniques for performing septoplasties as well as the aesthetic consequences of the operation become relevant. While SMR has historically been considered a procedure which will have little to no impact on nasal tip projection, recent research has shown that the nasal septum does in fact play a supporting role for nasal tip projection.<sup>7-9</sup> However, none of the previous research has explicitly detailed the techniques used for performing septoplasty.

It is important to note that this pattern of multiple maneuvers in 1 septoplasty is not standard. It is also uncommon that these maneuvers are performed in the specific order used in the study. Many surgeons do not even remove cartilage or bone. It is not surprising that projection is affected by removing enough cartilage to leave only an L-strut, which is further destabilized by the swinging door technique. Furthermore, maneuvers 2 through 5 are confounded by the previous maneuvers. They cannot be isolated because they are affected by the mechanical effects of the previous maneuvers. Also, cadaveric cartilage has properties that live human tissues do not. Thus, while the results of a cadaveric study cannot be truly translated to live patients, they can suggest the possibility that the same can occur in a live patient.

Although the current study used only a limited number of cadaveric specimens, it can be inferred that SMR of the nasal septal cartilage can result in loss of nasal tip projection. This is known, and it is consistent with previous studies. The study also shows that different maneuvers create different effects. The purpose of the study is not to give a firm conclusion based on 6 cadaver heads. This is a matter that should be investigated further. The study acts as somewhat as a pilot study, which can be extended into a

more formal study looking at the individual maneuvers on a larger scale.

While in some cadavers the loss is as little as 1 mm, it was as high as 3-mm change due to the addition of another maneuver. A 1-mm loss may not be noticeable, but a 3-mm change in projection in a short nose may be significant. Among the other procedures tested, no nasal tip projection was lost by simply dislocating the cartilaginous nasal septum from the posterior bony septum. The back-cut posteriorly along the bony-cartilaginous junction did not impact nasal tip projection in this study, while the anterior down-cut resulted in nasal tip projection loss in only 2 specimens, but the percent change in tip projection was less than the cartilage removal technique. These results may have been due to certain septal deformities or anatomic factors that existed in specific cadaver heads which resulted in varying degrees of reduction.

All cadaver heads underwent some loss of projection. More cadaver heads lost projection by the first maneuver than the other maneuvers. This may have been due to simply making a hemitransfixion incision and elevating soft tissue support. However, the destabilizing properties of various incisions has not been adequately assessed. Although none of the individual maneuvers assessed demonstrated statistically significant change, any loss of projection may be only accentuated over time. The loss of tip projection in these cadavers potentially underestimates the potential loss of projection which may occur in live patients. In live patients, the loss of tip projection would be accentuated by skin contracture. Over the course of months, the forces of skin contracture may depress the dorsum and shorten the columella. The remaining strut can be pulled in a ventral and cephalic direction. These changes become visibly apparent by 9 months.

## References

1. Maran AGD. Informed consent in head and neck surgery. *Clin Otolaryngol Allied Sci.* 1990;15:293-298.
2. Daws PJD. Informed consent: questionnaire survey of British Otolaryngologists. *Clin Otolaryngol Allied Sci.* 1994;19:388-393.
3. Phillipps JJ. The cosmetic effects of submucous resection. *Clin Otolaryngol Allied Sci.* 1991;16:179-181.
4. Vuyk HD, Langenhuijsen KJ. Aesthetic sequelae of septoplasty. *Clin Otolaryngol Allied Sci.* 1997;22:226-232.
5. Peacock MR. Submucous resection of the nasal septum. *J Laryngol Otol.* 1981;95:341-356.
6. Thomas JN. SMR: two year follow up survey. *J Laryngol Otol.* 1978;92:661-666.
7. Adams WP Jr, Rohrich RJ, Hollier LH, Minoli J, Thornton LK, Gyimesi I. Anatomic basis and clinical implications for nasal tip support in open versus closed rhinoplasty. *Plast Reconstr Surg.* 1999;103:255-261; discussion 262-264.
8. Daudia A, Alkhaddour U, Sithole J, Mortimore S. A prospective objective study of the cosmetic sequelae of nasal septal surgery. *Acta Otolaryngol.* 2006;126:1201-1205.
9. Johnson CM, Toriumi D. *A Case Approach to Open Structure Rhinoplasty.* 1st ed. Philadelphia: W.B. Saunders; 1990.

In addition to projection, it has been suggested that septoplasty can also lead to minor changes in the supra-tip and columella contours.<sup>8</sup> Many patients who undergo septoplasty specifically ask their surgeon whether a septoplasty will change the aesthetic appearance of their nose. Prior to surgery, septoplasty patients should be counseled regarding possible complication of cosmetic changes.

Especially in academic institutions, a SMR septoplasty is often considered a junior resident surgeon's case. Given the visual limitations monitor each maneuver, teaching septoplasty is difficult and often inadequate. The potential cosmetic outcome of septal surgery should call attention to the training of septoplasty. Young surgeons should be able to discern which maneuvers have a higher likelihood of producing cosmetic change.

In addition, otolaryngologists should be able to address loss of nasal tip projection (ie, tongue in groove/columellar strut) endonasally should the need arise. One of the challenges of septoplasty and rhinoplasty is that each nose has unique anatomy. This study did not attempt to identify other anatomic factors which may affect septoplasty. Pre-operative evaluation may help predict which maneuvers pose risk to projection. Palpation of nasal tip before and after septoplasty to see if nasal tip recoil has changed as well as palpation prior to surgery in order to determine the technique that should be used.

## Conclusion

Nasal septal surgery may change nasal tip projection. Surgeons should be aware of this and be able to compensate for loss of tip projection. During informed consent, patients should be made aware of this risk. 